

Research Article



Effect of *Cryptococcus neoformans* Isolated from Pigeon on Some Hematological, Biochemical and Histopathological Parameters by Experimental Infection in BALB/c Mice

ISA SWADI TOUHALI

Department of Microbiology, College of veterinary Medicine, Wasit University, Iraq.

Abstract | Back ground: Cryptococcosis is the most common systemic fungal infection in humans and animals which are easily isolated from avian excreta. Therefore, it's important to isolate them locally and to know their effect on public health by injecting them empirically into laboratory mice. **Methodology:** One hundred and fifty samples of pigeon droppings are collect from Wasit province, during January 2018 to March 2018. Twenty-four male adult mice type BALB/c is use, divided into two groups of 12 animals per group. One group which is consider as control, whereas other group is injected with suspension of *Cryptococcus neoformans* isolated from pigeon droppings as treatment group. Four animals from each group were killed every 3 days after injection serially (T1=3 days, T2=6 days, and T3=9 days respectively) to investigate the effects of *C. neoformans* for three injection periods on some hematological (RBC, WBC, PCV, Hb concentration, and differential WBC count), biochemical (serum ALT and AST activities) and histopathological parameters. **Results:** The result show twenty six droppings pigeon samples (17.3%) out of 150 samples were positive for the incidence of *C. neoformans* isolates and significant reduction of RBC, PCV ratio, and Hb concentration in all treated groups. While, WBC and differential WBC counts (nutrophils, monocyte and acidophil ratio) was significantly increased, while the lymphocyte and basophil ratio was reduced during the three periods of injection as compared to control. Also, the yeast suspension produced a significant elevation in the activities of serum ALT and AST with control group .but, the level of serum AST persist elevated with long injection period for 9 days than elevation of ALT comparison. As well as, data showed pathological alterations in organs (brain and lung) of mice. **Conclusion:** of present investigation indicates that prolong exposure of *C. neoformans* could mostly induced physiological alterations in blood picture, serum biochemistry and caused histopathological of brain and lung in *Cryptococcus* infected animals.

Keywords | *Cryptococcus neoformans*, Pigeon droppings, BALB/c mice

Editor | Kuldeep Dhama, Indian Veterinary Research Institute, Uttar Pradesh, India.

Received | March 12, 2018; **Accepted |** April 02, 2018; **Published |** May 17, 2018

***Correspondence |** Isa Swadi Touhali, Department of Microbiology, College of veterinary Medicine, Wasit University, Iraq; **Email:** issa.suadee@gmail.com

Citation | Touhali IS (2018). Effect of *cryptococcus neoformans* isolated from pigeon on some hematological, biochemical and histopathological parameters by experimental infection in balb/c mice. Adv. Anim. Vet. Sci. 6(5): 201-206.

DOI | <http://dx.doi.org/10.17582/journal.aavs/2018/6.5.201.206>

ISSN (Online) | 2307-8316; **ISSN (Print) |** 2309-3331

Copyright © 2018 Touhali. This is an open access article distributed under the Creative Commons Attribution License, which permits unrestricted use, distribution, and reproduction in any medium, provided the original work is properly cited.

INTRODUCTION

Cryptococcosis is a systemic mycosis affecting humans and a large variety of animals, subacute or chronic, life threatening caused by *Cryptococcus neoformans* is encapsulated yeast, an organism found in soil, often associated with pigeon droppings (Kwon-Chung et al., 2014). Cryptococcosis is considered an opportunistic fungal disease is greatly increased in immunocompromised patients, mainly among patients with AIDS and organ transplant recipient (Heiman et al., 2011). In spite of this, Cryptococcosis is

not limited to immunocompromised persons, as shown by the current occurrence in Vancouver among healthy individuals (Huang et al., 2004). Cryptococcosis in animal, dog and cat to causes upper respiratory infection and skin lesion (Thomson et al., 2006). In horse, are causes sinusitis and pneumonia but in cattle, goats and sheep it mainly causes mastitis and rarely pneumonia (Duncan et al., 2006). The isolates of *C. neoformans* in environmental surroundings, was often isolated from bird's excreta. Due to their high body temperature, pigeons and many such birds cannot acquire infected but can harbour the yeasts cells

(Anaissie, 2002). However, the excrement of these reservoir birds is a natural defense and ideal medium for the environmental continued existence of *C. neoformans* and they provide in the distribution of the fungal cells (Zarrin et al., 2010). Histopathological lesions observed are with varying degrees of response in each organ depending on several factors of which the numerous properties of *C. neoformans* which act as an intracellular as well as an extracellular pathogen, that contribute to its virulence and help to evade the immune response (Maxie, 2007). Due to that cryptococcosis as one of the zoonotic diseases, therefore the aims of present study to isolate of *C. neoformans* from pigeons and its effect on public health through to our knowledge of some blood, chemical and histological changes caused by *C. neoformans* in laboratory mice, this study is the first in Wasit province of Iraq.

MATERIAL AND METHODS

SAMPLING AND ISOLATION

One hundred and fifty samples of pigeon droppings are collect from 5 a variety of regions Wasit, Iraq, during January 2018 to March 2018. The samples are collect in sterile separate plastic test tubes and immediately transported to the laboratory in ice box. Two gram of each sample is put in a test tube with 10 ml of normal saline, Then all tubes are shaken by vortex mixer for 5min. and left for 15 min. Culturing is made from the supernatant part in Sabouraud dextrose Agar (BDH, England) plates with chlormphenicol (200 mg/L) and incubated at 37 °C for (3-10) days. Yeast isolates are diagnose according to cultural distinguishing, morphology culturing, shown of a capsule on India ink preparation and Urease test (Washington et al., 2006).

LABORATORY ANIMALS

In this experiment is use white male adult mice type BAL-B/c at 8-10 weeks in age and weight range 20-25 gm. They are have been obtained from the College of Education/ University of Thi Qar, and maintained at the animal's house of the faculty of veterinary medicine, Wasit University of Iraq. They are kept in mice cages and allowed free access to food and fresh water *ad libitum*.

YEAST INOCULA

The local isolate of *Cryptococcus neoformans* from pigeon droppings is grow on the Sabouraud Dextrose Agar (SDA) for 48 hours at 30°C followed by a aseptically sub culturing of a heavy inoculums to tubes containing 10 ml Sabouraud dextrose broth and is incubate for 24 hours at 30°C. Then it concentrated by centrifugation 3000 rpm for 15 minutes. The yeast cells are wash three times with sterilized normal saline for 5 minutes neglecting the floating fluid each time, and diluents with sterilized normal saline to form 1:100

which are shaken smoothly. Then they are count by using a hemocytometer and re-adjusted to be 1×10^6 cell /ml, simultaneously. Plating for the inoculums on the SDA is conduct to assure inoculums viability (Al-Tamemy, 2010).

STUDY DESIGN

Twenty four animals are divided into two groups of 12 animals per group, are use in this study. Twelve animals of first group are inject with 0.2 ml /animal (I/P) normal saline solution which consider as control group. Whereas other twelve animals injected with yeast suspension of *C. neoformans* in dose of 1×10^6 cell /animal (I/P) as treatment group. Four animals from each group are kill every three days after injection serially (T1, T2, and T3 respectively) to study physiological and histopathological parameters.

BLOOD AND SERUM SAMPLES

Blood is collect by cardiac puncture from both control and treatment mice by using a thin small gauche syringe are dispense into sterile tube with anticoagulant for hematological examination. Blood also collected into clean non-anticoagulant test tubes and allow to colt. The serum is separate from clot and centrifuged according to animal groups into clean test tubes for biochemical analysis.

DERERMINATION OF HEMATOLOGICAL PARAMETERS

Determination of hematological parameters (RBC, WBC, PCV, Hb, and leukocyte differential count is perform according to (Schalm, 1975).

DERERMINATION OF SERUM BIOCHEMICAL PARAMETERS

The activity of serum aspartate aminotransferase (GOT/AST) and alanine aminotransferase (GPT/ALT) is also measured in both groups (Reitman and Frankel, 1975).

HISTOPATHOLOGICAL EXAMINATIO

Biopsies of these organs (brain and lung) are also placed immediately in 10% formalin for fixation; the histopathological sections are process according to (Bancroft et al., 1990).

STATISICAL ANALYSIS

Statistical analysis is carry out using (VassarStats, 2010). All data are express as mean +/- SEM. For the analysis of the experimental parameters one-way ANOVA for independent samples followed by Tukey's HSD Post-hoc testis use. Value of $p < 0.05$ is consider to be statistically significant.

RESULTS

Twenty six droppings pigeon samples (17.3%) out of 150 samples are positive for the occurrence of *C. neoformans* isolates. The yeast colonies on Sabouraud dextrose agar is

Table 1: Effect of yeast suspension of *Cryptococcus neoformans* on some hematological parameters in male laboratory mice

Parameters	Control	T1	T2	T3
R.B.C (10 ⁶ /μL)	8.354±0.085	6.313±0.002 ^a	5.847±0.001 ^b	5.568±0.005 ^c
W.B.C(10 ³ /μL)	4.355±0.003	7.972±0.005 ^a	8.047±0.006 ^b	8.035±0.025 ^{bc}
P.C.V (%)	30.50±0.168	20.65±0.064 ^a	20.27±0.075 ^{ab}	18.95±0.064 ^c
Hb (%)	12.00±0.408	10.25±0.479 ^a	9.22±0.259 ^{ab}	8.42±0.246 ^{bc}

Values are mean ± SEM, n = 4

Groups with different superscript letters are significantly different versus control group (p < 0.05).

T1: Represented animals injected with yeast suspension of *Cryptococcus neoformans* for 3 days.

T2: Represented animals injected with yeast suspension of *Cryptococcus neoformans* for 6 days.

T3: Represented animals injected with yeast suspension of *Cryptococcus neoformans* for 9 days.

Table 2: Effect of yeast suspension of *Cryptococcus neoformans* on differential white blood cell count in male laboratory mice

Parameters	Control	T1	T2	T3
Nutrophils (%)	56.75±0.479	73.00±0.408 ^a	68.50±0.289 ^b	66.25±0.479 ^c
Lymphocyte (%)	36.50±0.645	24.50±0.645 ^a	22.50±0.645 ^{ab}	19.50±0.957 ^{bc}
Monocyte (%)	3.75±0.479	5.00±0.707 ^a	6.00±0.408 ^b	7.00±0.707 ^{bc}
Basophil (%)	1.00±0.000	0.00	0.00	0.00
Acidophil (%)	1.00±0.000	2.00±0.408 ^a	3.00±0.707 ^b	3.00±0.707 ^{bc}

Values are mean ± SEM, n = 4

Groups with different superscript letters are significantly different versus control group (p < 0.05).

T1: Represented animals injected with yeast suspension of *Cryptococcus neoformans* for 3 days.

T2: Represented animals injected with yeast suspension of *Cryptococcus neoformans* for 6 days.

T3: Represented animals injected with yeast suspension of *Cryptococcus neoformans* for 9 days.

Table 3: Effect of yeast suspension of *Cryptococcus neoformans* on some biochemical parameters in male laboratory mice

Parameters	Control	T1	T2	T3
GOT/AST (IU)	35.87±0.427	40.85±0.064 ^a	39.75±0.064 ^{ab}	38.00±0.408 ^c
GPT/ALT (IU)	15.40±0.082	19.05±0.320 ^a	21.30±0.082 ^b	22.00±0.408 ^{bc}

Values are mean ± SEM, n = 4

Groups with different superscript letters are significantly different versus control group (p < 0.05).

T1: Represented animals injected with yeast suspension of *Cryptococcus neoformans* for 3 days.

T2: Represented animals injected with yeast suspension of *Cryptococcus neoformans* for 6 days.

T3: Represented animals injected with yeast suspension of *Cryptococcus neoformans* for 9 days.

cream colored, smooth, mucoid, and developed to wrinkled whitish – creamy colonies after further incubation for 10 days, under microscopic are yeast cells show with India ink staining appeared as oval to spherical in shape cells surrounded by capsule and neither with hyphae nor pseudohyphae, all tested Twenty six isolates are positive for the urease test and showed the ability to utilize urea as indicated by changing the medium from yellow to pink.

HEMATOLOGY

The data of this study showed that yeast suspension caused a significant reduction (p>0.05) of RBC, PCV ratio, and Hb concentration in all treated comparison with control. Although, the reduced Hb concentration in all three treated periods (T1, T2, and T3) is no significant with the long injection period. While, WBC count is significantly increased in mice after administration of yeast suspension in

three injection periods (3, 6, and 9 days), but the increased of WBC level is no significant between last two of injection periods (T2 and T3) (Table 1). Also, the results of differential WBC count showed a significantly increased (p<0.05) of nutrophils, monocyte and acidophil ratio, while the lymphocyte and basophil ratio is significantly reduced (p>0.05) during the injection periods for 3, 6, 9 days as compared to control (Table 2).

BIOCHEMISTRY

Results presented in Table 3, show that yeast suspension of *C. neoformans* caused significant elevation (p>0.05) in the activities of both serum ALT and AST levels comparison with control group, but the elevation of ALT activity is no significant between T1 and T2. While, the elevation of serum AST level persist with long injection period for 9 days than elevation of ALT, although high AST activity

between T2 and T3 was no significant.

HISTOPATHOLOGY BRAIN

Histological assessment of the brain tissues are show various intensity of inflammation with a predominance of lymphocytes, and effectively no polymorph nuclear lymphocytes. Focal meningitis-(Figure 1A) associated with infiltration of lymphocytes and mononuclear cells with focal lymphatic cuffing (Figure 1B). Marked vacuolation of the grey matter as extensive cystic spaces to cavitations are frequently observed associated with yeast infiltration which in some sections showed budding process (Figure 1C). Controls are within normal limits (Figure 1D).

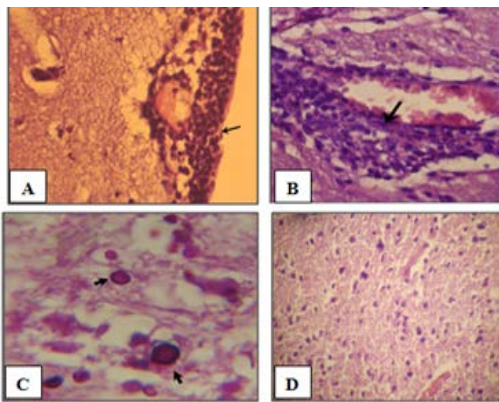


Figure 1: Histology of the male mouse brains and the effects of yeast suspension of *Cryptococcus neoformans*. Mice treated (T3) with dose of 1×10^6 cell/animal. A) Brain, meningitis- Lymphocytes, Monocytes infiltration (H&E. staining, x400). B) Brain, lymphocytic perivascular cuffing (H&E. staining, x400). C) Brain, graymatter vacuolation associated with *C. neoformans* infiltration (PAS ; x1000) D) Control (H&E. staining, x100)

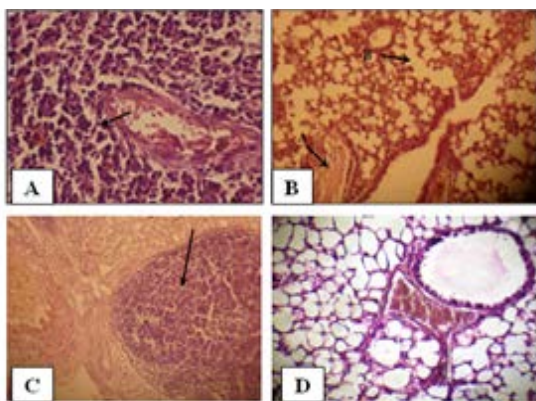


Figure 2: Histology of the male mouse lungs and the effects of yeast suspension of *Cryptococcus neoformans*. Mice treated (T3) with dose of 1×10^6 cell/animal. A) Lung, perivascular lymphoid aggregation (H&E. staining, x400). B) Lung, (arrow A) congestion and (arrow B) emphysema (H&E. staining, x400). C) Lung, nodule of mixed inflammatory cells (H&E. staining, x100) D) Control (H&E. staining, x400)

LUNG

Pulmonary sections examined. Cases of pneumonic consolidation characterize by areas of infiltration of mixed inflammatory cells, marked perivascular lymphoid aggregates (Figure 2A), dilated alveolar capillaries engorged with erythrocytes, infiltration of mixed inflammatory cells in the alveolar walls. An occasional alveoli are fill with amorphous, eosinophilic material with absence of an intraalveolar cellular filtrate also proliferation of lining epithelium in the bronchioles is observe. Congestion, edema and emphysema (Figure 2B) are abundant in most cases. There are tendency to form nodules of mixed inflammatory cells of polymorphnucleated leukocytes and mononuclear cells in the lungs of the affected animals (Figure 2). Controls (Figure 2D) are within normal limits.

DISCUSSION

The isolation of *C. neoformans* from the pigeon droppings in Wasit province recognized that avian habitats provide as an significant reservoir for this opportunistic pathogen and reported as essential substrates for the incidence and maintenance of *C. neoformans* in the environment (Majid et al.,2010). However, pigeons do not acquire cryptococcosis, most likely because *C. neoformans* can't grow at the pigeon's normal body temperature of 42°C (Anaissie et al., 2002). The present investigation indicate that infecting mice with *C. neoformans* is influent, as evidenced by hematological, biochemical and histological alterations. This study showed reduction of RBC count , PCV ratio, and Hb concentration are considered due to the systemic infections, involving spread of injected *C. neoformans* to the blood and/or other organs in mice. This data is consistent with the report of (Muret et al.,1995).which indicated that yeast caused infection which led to a plastic anemia. Reduction in RBC count and hemoglobin concentration may be due to the direct negative action of the yeast suspension on the mice by increased rate of suppression in the rate of RBC formation and/or breakdown of red cells which support with our finding in decreased PCV. So (Shakoori et al., 1990) suggested that the decrease in RBC count is either suggestive of excessive damage to erythrocytes or reticence of erythrocyte formation. In addition, the injection with yeast suspension of *C. neoformans* induced increases in the number of WBC, neutrophils, monocyte and acidophil ratio, while the ratio of lymphocyte and basophilis significantly reduced. This may be refer to induction of immune response in infected mice against yeast which known that white blood cell considered first defense against different infection (Provan et al., 2009).The polysaccharide capsule of *C. neoformans* play a role in the immune response creation, it stimulate natural immune effectors such as natural killer cells (NK), macrophages,(neutrophils) and mononuclear cells (lymphocytes and plasma cells), While the lymphocyte in our finding is

delay in increasing with prolong infection which in chronic infection. These cells consider the first line of defense in the immune system (Johnson et al., 1999). Additionally, (Rodriguez-Galan et al., 2003) refer to the role of neutrophil in controlling the spread of yeast, by limitation of yeast proliferation and invasion; Whereas notice in this investigation the acidophil is increase due to consider sign immune response for yeast infection occur increased when released histamine because destroy (Mast cells) eventually released histamine which assistant increased (WBC) especially acidophil. This study evaluated liver function for some serum biochemical characteristics by measuring the damaging effect *C. neoformans* on the activities of ALT\GPT and AST\GOT are manifested by increases in serum (ALT and AST) activities in comparison to control animals. This is may be due to from hepatic cellular damage by yeast suspension This finding is consistent with previous study (Nath et al., 2004) which indicated that Serum ALT and AST are also elevate with maximum elevation in yeast infected animals. ALT activity in serum results from hepatic cellular damage, the changes in the enzyme activity may also be due to vascular changes leading to hepatic vascular congestion. On the otherhand, AST is widely distributed in several tissues of the body, but the highest concentration is found in liver and muscle. So the increase in AST activity in the present study is speculatively due to liver damage. Although, the silica group showed an elevation in serum (ALT and AST).The our histopathological study showed marked pathological changes in brain and lungs organs. Brain lesions showed cavitations and this is report in other studies (Aldelem, 2003). The negligible inflammation maybe reflects the ability of this organism to efficiently avoid the host's immune system and also the low immune resistance inside the brain (Kozel, 1996). This can explain the poor inflammatory response surrounding some of the cavities observed in the brain and the yeast cells in the tissues when stained with special staining. In order to cause meningoencephalitis, the fungal cells must endure in the bloodstream and cross the blood-brain barrier and different mechanisms are project for that (Alvarez and Casadevall, 2007). While the severity and the formation of the destructive lesions in the lung sections is suggest to be due to the phospholipas and the proteolytic enzymes produced by the *C. neoformans* (Da Silva et al., 2006) and that phospholipas is necessary for the entry of *Cryptococcus* into the pulmonary lymphatics and the blood. In addition to the capsule role current studies using murine models and macrophage-like cell lines have concerned secreted phospholipas B in intracellular survival, growth, and replication of *C. neoformans* within macrophages. It has been projected that PLB initiates invasion of the lung interstitial by *Cryptococcus* since phospholipids is the pulmonary surfactant and the outer leaflet of mammalian cell membranes are favoured substrates of the enzyme (Santangelo et al., 2004). This can explain the tissue damage in the affected organs

and the profusion of the emphysematous lesions experiential in our study in many of the investigated lung sections as this enzyme can cause destruction to the alveolar walls. It has been projected that *C. neoformans* intracellular replication and phagocytic cells destruction are major apparatus of the pathogenic process for *Cryptococcus* infection in the lung and other tissues (Mitchell, 2006).

CONCLUSION

the present study show prolong exposure of *C. neoformans* could mostly induced physiological alterations in blood picture, serum biochemistry and caused histopathogenesis of brain , and lung in *C. neoformans* infected animals.

ACKNOWLEDGEMENTS

The author is grateful to all staff member of Microbiology Department College of Veterinary Medicine of Wasit University, for their help and cooperation.

CONFLICT OF INTEREST

The author declares that they have no competing interests.

AUTHORS CONTRIBUTION

All the authors contributed equally.

REFERENCES

- Aldelemy SSM (2003). Immunologic and diagnostic study of cryptococcosis. M. Sc. Thesis., College of veterinary medicine, University of Baghdad.
- Al-Tamemy HMJ (2009). Detection, serodiagnosis and histopathological study of environmental isolation of *Cryptococcus neoformans* in Basrah province. M. Sc. Thesis College of Vet. Med. University of Basrah
- Alvarez M, Casadevall A (2007). Cell-to-cell spread and massive vacuole formation after *Cryptococcus neoformans* infection of murine macrophages. BMC Immunol. 8: 16 <https://doi.org/10.1186/1471-2172-8-16>
- Anaissie EJ, McGinnis MR, Pfaller MA (2002). Clinical Mycology. 1st .ed. Churchill Livingstone, New York. Pp: 1-608.
- Bancroft JD, Stevens A, Turner DR (1990). Theory and practice of histological techniques. Churchill Livingstone, New York. Pp: 200.
- Da Silva EG, Baroni FD, Viani FC, Ruiz LD, Gandra RF, Auler ME, Dias AL, Gambale W, Paula CR (2006). Virulence profile of strains of *Cryptococcus neoformans* Var. grubii evaluation by experiment infection in Balb/c mice and correlation with exoenzyme activity. J. Med. Microbiol. 55: 139-142. <https://doi.org/10.1099/jmm.0.46206-0>
- Duncan C, Stephen C, Campbell J (2006). Clinical characteristics and predictors of mortality for *Cryptococcus gattii* infection in dogs and cats of southwestern British Columbia. Can. Vet. J. 47:993-8.

- Heiman J, Kozel TR, Kwon-Chung KJ, Perfect JR, Casadevall A (2011). Cryptococcus from human pathogen to model yeast. Washington, DC.
- Huang LMN, Maguire JA, Doyle P, Fyfe M, Roscoe DL (2004). Cryptococcus neoformans infection at Vancouver Hospital Center (1997-2002). J. Med. Microbiol. 53: 935-940. <https://doi.org/10.1099/jmm.0.05427-0>
- Johnson AG, Ziegler RJ, Lukasewycz OA, Hawley LB (1999). Microbiology and immunology. 3rd ed. Lippincott Williams & Wilkins. Philadelphia. Pp, 169-195.
- Kozel TR (1996). Activation of the complement system by pathogenic fungi. Clin. Microbiol. Rev. 9(1): 34-46.
- Kwon-Chung KJ, Fraser JA, Doering TL, Wang Z, Janbon G, Idnurm A, Bahn YS (2014). Cryptococcus neoformans and Cryptococcus gattii, the etiologic agents of cryptococcosis. Cold Spring Harb. Perspect. Med. 4(7): a019760. <https://doi.org/10.1101/cshperspect.a019760>
- Majid Z, Masoomah J, Nasrin A, Morad R (2010). Isolation of *Cryptococcus neoformans* from pigeon droppings in Ahwaz, Iran Turk. J. Med. Sci. 40 (2): 313-316
- Maxie MG (2007). Pathology of domestic animals. 5th ed. Elsevier Saunders Ltd. Toronto. Pp: 642-644
- Mitchell AP (2006). Cryptococcal virulence: beyond the usual suspects. J. Clin. Invest. 116(6): 1481-1483. <https://doi.org/10.1172/JCI28842>
- Muret A, Machet B, Grangeponde MC (1995). Cutaneous candidiasis due to *Candida parapsilosis* occurring in the course of idiopathic a plastic anemia. Am. Pathol. 15(4):276-279.
- Nath RA, Charan K, Dey S, Swarup D, Singh BR (2004). Hematological and biochemical alterations in cadmium inhalation on experimental pulmonary candidiasis in rabbits. Indian J. Vet. Pathol. 28(2): 106-112.
- Provan D, Singer CRJ, Baglin T (2009). Oxford handbook of clinical hematology 3th ed. New York, Pp:31-109. <https://doi.org/10.1093/med/9780199227396.001.0001>
- Reitman S, Frankel SA (1975). A colorimetric method for the determination of serum.
- Rodrigues-Galan MC, Sotomayor C, Costamagna ME, Cabanillas AM, Renteria BS, Masini-Repiso AM, Correa S (2003). Immunocompetence of macrophages in rats exposed to *Candida albicans* infection and stress. Am. J. Physiol. Cell Physiol. 284: 111-118. <https://doi.org/10.1152/ajpcell.00160.2002>
- Santangelo R, Zoellner H, Sorrell T, Wilson C, Donald C, Djordjevic J, Shounan Y, Wright L (2004). Role of extracellular phospholipases and mononuclear phagocytes in dissemination of cryptococcosis in a murine model. J. Infect. Immun. 72(4): 2229-2239. <https://doi.org/10.1128/IAI.72.4.2229-2239.2004>
- Schalm OW, Jain NC, Carroll EJ (1975). Veterinary hematology .3 rd Lee and Febiger, Philadelphia;807.
- Shakoori AR, Aziz F, Alam J, Ali SS (1990). Toxic effects of talstar, a new synthetic pyrethroid, on blood and liver of rabbits. Pak. J. Zool. 22(3): 289-300.
- Thomson P, Miranda J, Silva V (2006). Canine lymphadenitis caused by *C. neoformans*. Rev. Lberoam. Micol. 23: 238-240. [https://doi.org/10.1016/S1130-1406\(06\)70052-3](https://doi.org/10.1016/S1130-1406(06)70052-3).
- VassarStats: [homepage on the internet] (2010): Website for Statistical Computation, Vassar College, Poughkeepsie, NY, USA. Available in: <http://faculty.vassar.edu/lowry/VassarStats.html>. Accessed in Aug. 12th 2010.
- Washinton WJ, Stephan A, William J, Elmer K, Gail W Konemans (2006). Color Atlas and Textbook of diagnostic Microbiology. 6th edd:1152-1232.
- Zarrin M, Jorfi M, Amirrajab N, Rostami M (2010). Isolation of *Cryptococcus neoformans* from pigeon droppings in Ahwaz, Iran. Turk. J. Med. Sci. 40: 313-6.