



Trypanosoma vivax Epizootic Infection in Cattle from Espírito Santo State, Brazil

RABECHE SCHMITH¹, WINNY SILVA MOREIRA¹, JEFERSON MIGUEL VASSOLER¹, JÚLIO CESAR VASSOLER¹, JOSÉ EDUARDO GUIMARÃES DE BRITTO SOUZA¹, ALEXANDRE GRANADOS AFONSO DE FARIA¹, LEONARDO CAMPOS ALMEIDA¹, MARIANA CAETANO TEIXEIRA², CLAIRTON MARCOLONGO-PEREIRA^{1*}

¹Faculty of Veterinary Medicine, Centro Universitário do Espírito Santo – UNESC, Colatina, Brazil; ²Faculty of Veterinary Medicine, Centro Universitário Ritter dos Reis–UniRitter, Porto Alegre, Brazil.

Abstract | Bovine trypanosomiasis is a parasitic disease caused by the protozoan *Trypanosoma vivax*. This disease causes high morbidity and mortality in the herd and is thus responsible for low economic savings in cattle farming. The objective of this study was to report the occurrence of trypanosomiasis due to *T. vivax* in Espírito Santo, Brazil. The animals had reduced milk production, intermittent fever, anorexia, apathy, births of weak cattle, and adult mortality after progressive weight loss. Complete blood count and hematozoa were investigated. In the hematological analysis, the trypomastigote form of *T. vivax* was observed. This was the first report of the occurrence of *T. vivax* in the State of Espírito Santo. The results of this paper show the importance of carrying out studies to diagnose the epidemiological situation of the disease within the productive context of regions that manage dairy farming with severe symptoms of the disease. Therefore, the occurrence of trypanosomiasis can have a negative impact on the health and economics of local cattle farming.

Keywords | Bovine, *Trypanosoma vivax*, Parasite, Infection

Received | March 13, 2020; **Accepted** | May 19, 2020; **Published** | May 25, 2020

***Correspondence** | Clairton Marcolongo-Pereira, Faculty of Veterinary Medicine, Centro Universitário do Espírito Santo–UNESC, Rua Fioravante Rossi 2930, Bairro Martinelli, Colatina-ES, Brazil, 29703-858; **Email:** clairton.marcolongo@terra.com.br

Citation | Schmith R, Moreira WS, Vassoler JM, Vassoler JC, Souza JEG, Faria AGA, Almeida LC, Teixeira MC, Marcolongo-Pereira C (2020). *Trypanosoma vivax* epizootic infection in cattle from Espírito Santo State, Brazil. Adv. Anim. Vet. Sci. 8(6): 629-632.

DOI | <http://dx.doi.org/10.17582/journal.aavs/2020/8.6.629.632>

ISSN (Online) | 2307-8316; **ISSN (Print)** | 2309-3331

Copyright © 2020 Schmith et al. This is an open access article distributed under the Creative Commons Attribution License, which permits unrestricted use, distribution, and reproduction in any medium, provided the original work is properly cited.

INTRODUCTION

Bovine trypanosomiasis is a parasitic disease caused by the protozoan *Trypanosoma vivax*. This disease causes high morbidity and mortality in the herd, and is thus responsible for significant economic losses in cattle (Lopes et al., 2018). The transmission of the disease-causing agent occurs mainly through the blood meal of blood-sucking insects (Vieira et al., 2017). In African countries, where the disease is widely distributed, the main biological vector is the tsetse fly, whereas in the Americas, the flies: *Stomoxys calcitrans* and *Tabanus spp.* predominate as vectors (Reis et al., 2019). In addition, transmission can occur via iatrogenic means: application of drugs, blood transfusions, and fomites (Vieira et al., 2017).

Animals infected with the parasite can present the following forms: acute, chronic, or asymptomatic, and the main clinical signs are characterized by reduced milk production, acute anemia, anorexia with progressive weight loss, hyperthermia, reproductive problems including abortions, and neurological signs (Vieira et al., 2017; Pereira et al., 2018).

The diagnosis of the disease can be made by a combination of assessment of the clinical picture and parasitological, serological, and molecular techniques. In general, the diagnostic methods used to identify *T. vivax* are the detection of the hemoparasite by means of direct blood smear, serological assays such as indirect immunofluorescence assay (IFA) (Guerra et al., 2013), enzyme-linked immunosorbent assay (ELISA) (Madruga

et al., 2006), and molecular detection by polymerase chain reaction (PCR) (Vieira et al., 2017).

In recent years, there has been a greater record of outbreaks of bovine trypanosomiasis in Brazil (Barbosa et al., 2015; Pereira et al., 2018). The present study aimed to report the occurrence and risk factors associated with *T. vivax* infection in cattle in the State of Espírito Santo, Brazil.

CASE DESCRIPTION

The study was carried out in 2019 on a dairy property located in the municipality of Aracruz, Espírito Santo. The farm herd consisted of Girolando cows, with a total production of 360 liters per day and an average of 16.36 kg milk per cow per day. The production system adopted was intensive rotated grazing, with two mechanized milking daily.

There were 22 cows on the property, 10 of which had clinical signs of the disease, characterized by Decreased milk production, intermittent fever, anorexia, apathy, birth of weak calves, and mortality of adult animals after progressive weight loss, were reported by the owner. For diagnostic confirmation, whole blood samples were collected from the symptomatic cattle via jugular venipuncture. The collected samples were stored in 4-mL sterile tubes with EDTA anticoagulant.

Complete blood count was performed using an automated hematology analyzer (URIT-3000 Vet Plus – MHLab®), calibrated to cattle as recommended by the manufacturer. Slides for protozoan investigation and differential blood count were prepared. The slides were fixed in methanol and stained using Giemsa, and were examined under immersion on optical microscope. In the hematological examinations, the alterations observed were normochromic normocytic anemia, thrombocytopenia, and leukocytosis in all animals. In the slides analysis, the trypomastigote form of *T. vivax* was observed (Figure 1).

All cattle in the herd, after identifying the parasite in the blood samples, were treated with intramuscular isometamidium hydrochloride, at a dose of 1.0 mg/kg. Forty days later, the animals received a new dose of the drug, at a dose of 0.5 mg/kg.

Fifteen days later, a new blood test to check for hematozoa on the previously positive animals as well as molecular detection by PCR were carried out.

Genomic DNA was extracted from 200 µl of bovine blood using a commercial kit (Qiagen DNeasy blood and tissue kit; Hilden, Germany) following the manufacturer's recommendations. PCR was performed as described by

Ventura et al. (2001) and modified by Cuglovici et al. (2010), using the primers 18S TviSL1 and TviSL2, which amplified a fragment of 210 bp.

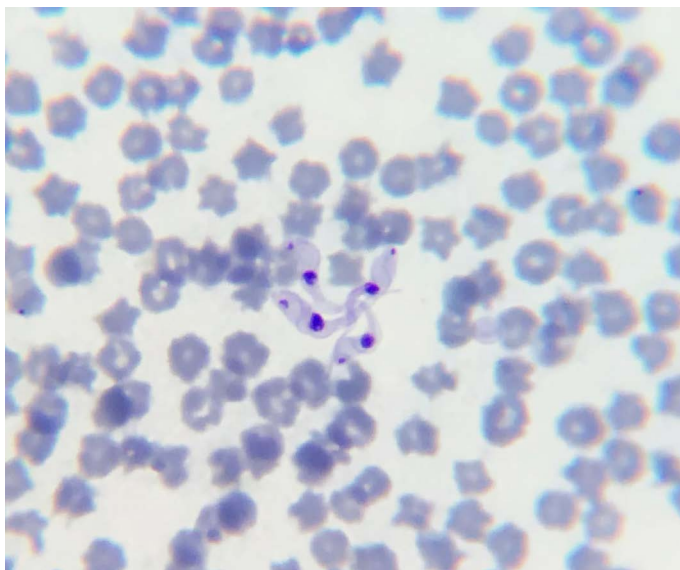


Figure 1: Trypomastigote forms of *T. vivax* with rounded posterior end, a weakly developed undulating membrane, central nucleus and terminal kinetoplast.

T. vivax was not observed in blood samples taken after treatment, nor were fragments of parasite DNA amplified in the PCR.

Trypanosoma vivax was not observed in blood samples taken after treatment, nor were fragments of parasite DNA amplified

DISCUSSION

The diagnosis of trypanosomiasis was based on assessment of clinical and epidemiological characteristics, and observation of the trypomastigote forms of the parasite in blood smears. These forms observed had a rounded posterior end, a weakly developed undulating membrane, central nucleus and terminal kinetoplast, characteristic of *T. vivax* (Hoare, 1972). *Trypanosoma vivax* has been mentioned as the main species that affects cattle in Brazil (Reis et al., 2019). The diagnosis of infection by this species of parasite is made on the basis of identification of the parasite's morphology, characterized by a sickle shape, with an obtuse posterior end, a wavy membrane, a large central nucleus, a terminal kinetoplast, and a free flagellum (Lopes et al., 2018; Reis et al., 2019).

It is noteworthy that the cattle on the property began to fall ill soon after animals from other regions of Brazil, mainly from the State of Minas Gerais, were introduced into the property. It was suggested that the protozoan was introduced through the acquisition of animals with subclinical infection, acquired without examination and

prior knowledge of their health status. The movement and commercialization of animals in the absence of adequate sanitary control is one of the most important risk factors for the occurrence of outbreaks of the disease as well as for its spread (Barbosa et al., 2015). In addition, the incidence of the disease probably increased within the property, through the use of shared needles, especially during the injection of the hormone, oxytocin, which is used to help eject milk. Barbosa et al. (2015) reported the relationship between outbreaks in Goiás, and the daily administration of oxytocin in cows, intravenously, before milking, using the same needle and syringe.

Another factor that may have contributed to the expansion of cases on the property was the presence of *Stomoxys calcitrans*. The blood meal of this hematophagous insect plays an important role in the transmission of *T. vivax*. in Brazil. Cadioli et al. (2012) reported *Stomoxys calcitrans* as the main epidemiological factor for the occurrence of the disease in an outbreak, in dairy cattle, in the State of São Paulo, while Lopes et al. (2018) associated the increase in cases of Trypanosomiasis to the presence of *Tabanus* spp. and *S. calcitrans* in Parnaíba, Piauí.

In this study, the animals showed marked anemia. Anemia is described as one of the main findings of trypanosomiasis, which may be a consequence of some pathological events such as decreased erythropoiesis, vascular hemolysis, erythrophagocytosis and inadequate hematopoiesis (Batista et al., 2008; Lopes et al., 2018; Pereira et al., 2018).

Disease control can be achieved through drugs such as diminazene acetate and isometamidium hydrochloride (Cadioli et al., 2012). However, in order to effectively control the disease, it is necessary, in addition to treating the affected animals, to restrict the movement of sick cattle, monitor the distribution of the disease, and control the vectors (Mbewe et al., 2015). After treating the animals with isometamidium hydrochloride, the blood smear and the PCR result for *T. vivax* was negative, as observed in another study (Reis et al., 2019).

CONCLUSION

This was the first report of the occurrence of *T. vivax* in the State of Espírito Santo. The results of this study show the importance of carrying out new studies to determine the epidemiological situation of the disease within the productive context of regions that manage dairy farming with severe symptoms of the disease. Therefore, the occurrence of trypanosomiasis can have a negative impact on the health and economics of local cattle farming.

ACKNOWLEDGEMENT

To Fundação de Amparo à Pesquisa e Inovação do Estado do Espírito Santo - FAPES for granting the necessary financial support for the development of this study.

AUTHORS CONTRIBUTION

All authors were actively involved in the study and approved the final draft of this manuscript.

CONFLICT OF INTEREST

The authors have no competing interests.

REFERENCES

- Barbosa JC, Bastos TSA, Rodrigues RA Madrid DMC, Faria AM, Bessa LC, Linhares GFC (2015). Primeiro surto de tripanossomose bovina detectado no estado de Goiás, Brasil. *Ars Vet.*, 31 (2): 100. <https://doi.org/10.15361/2175-0106.2015v31n2p100>
- Batista JS, Bezerra FSB, Lira RA, Carvalho JRG, Neto AMR, Petri AA, Teixeira MMG (2008). Aspectos clínicos, epidemiológicos e patológicos da infecção natural em bovinos por *Trypanosoma vivax* na Paraíba. 28 (1): 63-69. <https://doi.org/10.1590/S0100-736X2008000100010>
- Cadioli FA, Barnabé PA, Machado RZ, Teixeira MCA, André MR, Sampaio PH, Junior OLF, Teixeira MMG, Marques LC (2012). First report of *Trypanosoma vivax* outbreak in dairy cattle in São Paulo state, Brazil. *Revista Brasileira de Parasitologia Veterinária*. 21 (2): 118-124. <https://doi.org/10.1590/S1984-29612012000200009>
- Cuglovici DA, Bartholomeu DC, Reis-Cunha JL, Carvalho AU, Ribeiro MFB (2010). Epidemiologic aspects of an outbreak of *Trypanosoma vivax* in a dairy cattle herd in Minas Gerais state, Brazil. *Vet. Parasitol.* 169 (3/4): 320-326. <https://doi.org/10.1016/j.vetpar.2009.12.041>
- Guerra NR, Monteiro MFM, Sandes HMM, Cruz NLN, Ramos CAN, Santana VLA, Souza MMA, Alves LC (2013). Detecção de anticorpos IgG anti-*Trypanosoma vivax* em bovinos através do teste de Imunofluorescência indireta. *Pesq. Vet. Bras.* 33 (12): 1423-1426. <https://doi.org/10.1590/S0100-736X2013001200005>
- Hoare CA (1972). The trypanosomes of mammals. In: A zoological monograph. Classification, Blackwell Scientific Publications, Oxford, UK: 60-80.
- Lopes STP, Prado BS, Martins GHC Beserra HEA, Filho MACS, Evangelista LSM, Cardoso JFS, Mineiro ALBB, Souza JAT (2018). *Trypanosoma vivax* em bovino leiteiro. *Acta Sci. Vet.*, 46: 1-5. <https://doi.org/10.22456/1679-9216.86772>
- Madruga CR, Araújo FR, Cavalcante-Goes G, Martins C, Pfeifer IB, Ribeiro LR, Kessler RH, Soares CO, Migueta M, Melo EPS, Almeida RFC, Lima Jr (2006). The development of an enzyme-linked immunosorbent assay for *Trypanosoma vivax* antibodies and its use in epidemiological surveys. *Mem. Inst. Oswaldo Cruz.*, 101(7): 801-807. <https://doi.org/10.1590/S0074-02762006000700016>
- Mbewe NJ, Namangala B, Sitali L Vorster I, Michelo C (2015). Prevalence of pathogenic trypanosomes in anaemic cattle from trypanosomosis challenged áreas of Itezhi-tezhi

- district in central Zambia. *Parasit. Vectors.* 8: 1-6. <https://doi.org/10.1186/s13071-015-1260-0>
- Pereira HD, Simões SVD, Souza FAL, Silveira JAG, Ribeiro MFB, Cadioli FA, Sampaio PH (2018). Aspectos clínicos, epidemiológicos e diagnóstico da infecção por *Trypanosoma vivax* em rebanho bovino no estado do Maranhão. *Pesq. Vet. Bras.*, 38(5): 896-901. <https://doi.org/10.1590/1678-5150-pvb-5303>
 - Reis MO, Souza FR, Albuquerque AS, Monteiro F, Oliveira LFS, Raymundo DL, Wouters F, Wouters ATB, Peconick AP, Varaschin MS (2019). Epizootic Infection by *Trypanosoma vivax* in Cattle from the State of Minas Gerais, Brazil. *Korean J. Parasitol.*, 57 (2): 191-195. <https://doi.org/10.3347/kjp.2019.57.2.191>
 - Ventura RM, Paiva F, Silva RA, Takeda GF, Buck GA, Teixeira MM (2001). *Trypanosoma vivax*: characterization of the spliced-leader gene of a Brazilian stock and species-specific detection by PCR amplification of an intergenic spacer sequence. *Exp. Parasitol.* 99 (1): 37-48. <https://doi.org/10.1006/expr.2001.4641>
 - Vieira OLE, Macedo LO, Santos MAB, Silva JABA, Mendonça CL, Faustino MAG, Ramos CAN, Alves LC, Ramos RAN, Carvalho GA (2017). Detection and molecular characterization of *Trypanosoma (Duttonella) vivax* in dairy cattle in the state of Sergipe, northeastern Brazil. *Revista Brasileira de Parasitologia Veterinária.* 26(4): 516-520. <https://doi.org/10.1590/s1984-29612017048>